

# Malaria Infection through Multiorgan Donation: An Update From Spain

**Montserrat Rodriguez,<sup>1</sup> Santiago Tome,<sup>1</sup> Luis Vizcaino,<sup>2</sup> Javier Fernandez-Castroagudin,<sup>3</sup> Esteban Otero-Anton,<sup>1</sup> Esther Molina,<sup>3</sup> Jorge Martinez,<sup>4</sup> Gloria De la Rosa,<sup>5</sup> Jose Lovo,<sup>6</sup> and Evaristo Varo<sup>4</sup>**

<sup>1</sup>Department of Internal Medicine, Complejo Hospitalario Universitario de Santiago, Santiago, Spain;

<sup>2</sup>Department of Biochemistry, Complejo Hospitalario Universitario de Santiago, Santiago, Spain;

<sup>3</sup>Department of Gastroenterology, Complejo Hospitalario Universitario de Santiago, Santiago, Spain;

<sup>4</sup>Department of Surgery, Complejo Hospitalario Universitario de Santiago, Santiago, Spain; <sup>5</sup>Organización Nacional de Trasplantes (ONT), Madrid, Spain; <sup>6</sup>Department of Microbiology, Complejo Hospitalario Universitario de Santiago, Santiago, Spain

During the last years, immigration has increased and, consequently, the pool of foreign donors and associated infectious diseases from exotic countries (especially from the tropics) has also increased. Only a few cases of malaria transmitted via different donation sources have been published. In the present report, a *Plasmodium vivax* transmitted through a multiorgan donation is reported. In conclusion, we discuss the features related with the diagnosis, the treatment, and the special characteristics of a case in which the liver and not any other organ is the reservoir of the plasmodium. *Liver Transpl* 13: 1302-1304, 2007. © 2007 AASLD.

Received February 25, 2007; accepted April 9, 2007.

Infectious diseases are an important cause of morbidity-mortality after solid organ transplantation. They can arise from latent infections, "de novo," or they can be transmitted from the donor. In recent years immigration from tropical countries has increased progressively. As the pool of foreign donors has increased with a corresponding increase in exotic infections, unusual infections such as human T-cell lymphotropic virus I and II, coccidiomycosis, histoplasmosis, blastomycosis, leishmaniasis, and malaria now represent a threat during the posttransplantation period.<sup>1</sup>

Malaria is not a common infection in transplant recipients. In fact, only a few cases have been reported after kidney, liver, heart, and bone marrow transplants. All species of *Plasmodium* causing human infection (*P. falciparum*, *P. vivax*, *P. ovale*, and *P. malariae*) can be transmitted by the graft. The outcome seems to be related not only to early diagnosis but also to prompt and early treatment.<sup>2</sup>

In this work, a malaria case of *Plasmodium vivax*

transmitted via the hepatic allograft from a multiorgan donation is presented.

## CASE REPORT

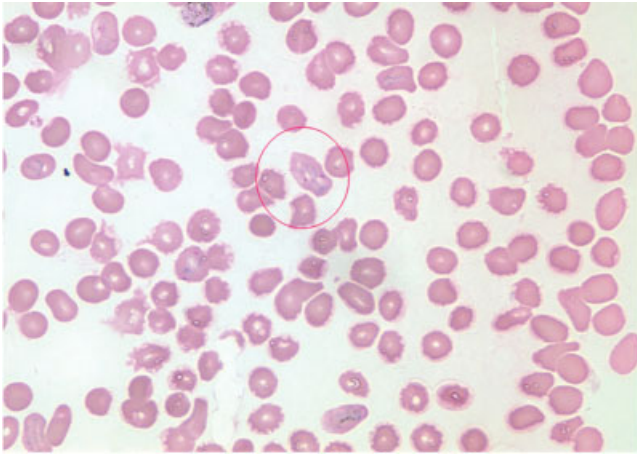
A 30-yr-old male underwent orthotopic liver transplantation because of hepatic acute failure due to the hepatitis B virus. He received a graft from a 27-yr-old male multiorgan donor who died as a consequence of spontaneous cerebral hemorrhage. The donor was born in Bolivia, had lived in Colombia, and had spent the last year of his life in Spain. He had malaria 3 yr ago and underwent a successful malaria treatment, leaving him asymptomatic to the moment of his death. During the organ donation process, a thick blood smear was performed with negative result. The lungs, heart, pancreas, and kidneys were transplanted to patients in different Spanish hospitals.

The postoperative course was uneventful but on the 21st posttransplantation day, the patient suddenly pre-

Address reprint requests to Santiago Tome, Liver Unit, Department of Internal Medicine, Hospital clinico Universitario de Santiago, Choupana s/n 15706, Santiago, Spain. Telephone: 34-981-951277; FAX: 34-981-950-622; E-mail: santiagotomemar@yahoo.es

DOI 10.1002/lt.21219

Published online in Wiley InterScience (www.interscience.wiley.com).



**Figure 1. Erythrocytes with double parasites. Giemsa stained blood smear.**

sented fever with chills and hypotension without an apparent infectious origin. Broad spectrum antibiotic treatment was begun with an unsuccessful outcome. The blood smear disclosed pancytopenia, hemolysis, and a high amount of intracellular parasites compatible with *Plasmodium*. The microbiological study confirmed a *P. vivax* infection and it is important to note that double parasitization was seen in the erythrocytes (Fig. 1). A course of chloroquine (total dose: 1,500 mg) with primaquine (15 mg/day for 14 days, total dose: 210 mg) was started and the fever disappeared in 48 hours. At the same time the blood parasitization decreased considerably after 48 hours. The tolerance to the medication was moderately good without either liver or hematologic toxicity.

Two months later the patient was admitted again with a reappearance of the fever. A total of 80% of the erythrocytes were observed to have intracellular parasites. He received the same dose of chloroquine (total dose: 1,500 mg) and a double dose of primaquine (30 mg/day for 14 days, total dose: 420 mg); the treatment schedule produced complete resolution of his condition and there was no further relapse.

A pancreas-kidney and lungs from the same donor were transplanted into 2 different recipients. One yr later, they did not develop malaria, the thick smears were negative, and no treatment for malaria was given. Two additional patients who received heart and right kidney grafts were asymptomatic; however, as the thick smears were positive they were treated and so far they are and have been asymptomatic.

## DISCUSSION

Malaria is a rare parasitic infection in patients who live outside of endemic zones. Although the mosquito's bite or a reactivation of the latent disease are the common mechanisms by which the disease is acquired in non-compromised patients, in transplant patients, blood transfusions or infected grafts are the most frequent means of transmission.<sup>3</sup> Most of the cases in which

malaria developed were through renal grafts,<sup>4-6</sup> although some cases of malaria had also been transmitted by liver,<sup>2,7-9</sup> heart,<sup>2</sup> and bone marrow grafts.<sup>10</sup> In the liver transplant arena, only 5 cases have been well documented. One of them was a result of platelet transfusion and the others resulted from liver grafts. The plasmodia species was identified in all cases. In 4 of the cases *P. falciparum* was the cause<sup>2,3,8,9</sup> while *P. vivax* was the cause in the fifth case.<sup>7</sup> As the donation was multiorgan, 2 patients developed malaria with grafts from sources other than the liver.<sup>2,7</sup>

Our patient had never traveled to an endemic malaria area. And on top of this, recipients from the same donor have also developed malaria, which means the donor was the origin of the disease. Therefore, in this case as in others,<sup>7</sup> the disease resulted from an immunosuppressed host due to the reactivation of plasmodia residing in the liver donor. However in the cardiac, kidney, and lung recipients, the disease can only be explained by subclinical and lower parasitemia in the donor.<sup>7</sup>

Effective differential diagnosis of infectious diseases may be crucial in order to make a correct early diagnosis. The prognosis of a malaria case in a transplant patient seems to be influenced by the type of transplanted organ, the plasmodium species, the immunosuppressive treatment, and the delay in the onset of antimalarial treatment.<sup>2</sup> In kidney transplant cases, the clinical outcome may well be better than in liver or cardiac transplantation; types of immunosuppression, time of organ collection and ischemia time have been put forward as possible causes.<sup>2</sup> There is also a correlation between the degree of parasitemia and the severity of the disease.<sup>2</sup> Nevertheless, the main prognostic factor is the ability to perform a rapid diagnosis and to deliver effective treatment.<sup>2</sup> Serial measurements of parasitemia together with clinical information are very useful.<sup>11</sup> In the case reported here, the degree of parasitization was considerable; however, the early treatment led to a quick clinical and microbiological response. In order to eliminate exoerythrocytic plasmodium as well as treating the acute phase, *P. vivax* and *P. ovale* required treatment with primaquine to eradicate any hypnozoite forms that may have remained dormant in the liver in order to prevent relapses.<sup>11</sup> Recent articles report *P. vivax* cases that were initially treated successfully with chloroquine and primaquine and later suffered subsequent relapse due to primaquine tolerance. The use of doses higher than 15  $\mu$ /day in order to prevent this risk has also been reported.<sup>12</sup> In the present case the immunosuppressive status as well as low doses of primaquine, and the fact the organ in question was the liver and not any other, might explain why the patient relapsed. Nowadays the recommended treatment is a primaquine dose of 30 mg/day or 0.5 mg/kg for 14 days, together with a schizonticidal drug (chloroquine or quinine) in the acute phase.<sup>13</sup>

In the last years there has been a considerable increase in the immigrant population, the number of foreign donors and the number of trips abroad. Because of this any immigrant or native donor who has traveled abroad, especially to tropical zones in the last 5 yr,

should be tested for the most prevalent infections endemic to each zone. A thorough screening is crucial because as with the case reported here, the donor may be asymptomatic and, moreover, may have a negative thick blood smear simply as a result of lower parasitemias. In the case of multiorgan donation, all recipients should be screened as if they were asymptomatic.<sup>7</sup> Today, there are no clear rules as to whether asymptomatic patients with negative thick blood smears should receive preventive treatment or periodically repeat the thick blood smear.<sup>2</sup>

In conclusion, malaria in the context of liver transplantation continues to be a rare disease; however, as a result of increased travel to endemic zones and of the increase in the number of immigrants as potential donors, we should be wary of uncommon infections that the recipients may acquire through transplant procedures. Since the initial clinical picture is not always typical and it may lead to erroneous conclusions, accurate early diagnosis in order to begin early treatment is essential.

## REFERENCES

1. Angelis M, Cooper JT, Freeman RB. Impact of donor infections on outcome of orthotopic liver transplantation. *Liver Transpl* 2003;9:451-462.
2. Chiche L, Lesage A, Duhamel C, Salame E, Malet M, Samba D, et al. Posttransplant malaria: first case of transmission of *Plasmodium falciparum* from a white multiorgan donor to four recipients. *Transplantation* 2003;75:166-168.
3. Talabiska DG, Komar MJ, Wytock DH, Rubin RA. Posttransfusion acquired malaria complicating orthotopic liver transplantation. *Am J Gastroenterol* 1996;91:376-379.
4. Turkmen A, Sever MS, Ecder T, Yildiz A, Aydin AE, Erkok R, et al. Posttransplant malaria. *Transplantation* 1996;62:1521-1523.
5. Nuesch R, Cynke E, Jost MC, Zimmerli W. Thrombocytopenia after kidney transplantation. *Am J Kidney Dis* 2000;35:537-538.
6. Bemelman F, De Block K, De Vries P, Surachno S, Ten Berge I. Falciparum malaria transmitted by a thick blood smear negative kidney donor. *Scand J Infect Dis* 2004;36:769-771.
7. Fischer L, Sterneck M, Costard-Jackle A, Fleischer B, Herbst H, Rogiers X, et al. Transmission of malaria tertiana by multi-organ donation. *Clin Transplant* 1999;:491-495.
8. Crafa F, Gugenheim J, Fabiani P, Di Marzo L, Militerno G, Iovine L, et al. Possible transmission of malaria by liver transplantation. *Transplant Proc* 1991;23:2664.
9. Menichetti F, Bindi ML, Tascini C, Urbani L, Biancofiore G, Doria R, et al. Fever, mental impairment, acute anemia, and renal failure in patient undergoing orthotopic liver transplantation: posttransplantation malaria. *Liver Transpl* 2006;12:674-676.
10. Lefrere F, Besson C, Datry A, Chaibi P, Leblond V, Binet JL, et al. Transmission of *Plasmodium falciparum* by allogenic bone marrow transplantation. *Bone Marrow Transplant* 1996;18:473-474.
11. No authors listed. Parasitic infections. *Am J Transplant* 2004;4(Suppl 10):142-155.
12. Baird JK, Hoffman SL. Primaquine therapy for malaria. *Clin Infect Dis* 2004;39:1336-1345.
13. Centers for Disease Control and Prevention (CDC). National Center for Infectious Diseases, Division of Parasitic Diseases. Treatment of Malaria (Guidelines For Clinicians). Available at: [http://www.cdc.gov/malaria/diagnosis\\_treatment/tx\\_clinicians.htm](http://www.cdc.gov/malaria/diagnosis_treatment/tx_clinicians.htm). Last accessed: May 24, 2007.